

# HEALTHY EYES

Information for patients



Type 2 diabetes mellitus

Disease Management Programme



# HEALTHY EYES IN CASES OF TYPE 2 DIABETES MELLITUS – WHAT CAN I DO?

**More and more people are getting type 2 diabetes mellitus. Damage to the eyes is a possible later consequence that is to be taken seriously. If the diabetes mellitus is not diagnosed at an early stage and correctly treated, it can lead to serious problems.**

Therefore, do not let it get to that stage! The more you do actively for your health, the better the effect will be on the course of your disease. Take note of the following points in this regard:

## **A balanced diet**

It is best to choose a combination of plenty of fresh fruit and vegetables, wholegrain products and few animal foods. Try to eat as little sugar and fat as possible – ideally sugar-free!

## **Adequate exercise**

Introduce more exercise to your everyday life and increase it gradually. Discuss with your doctor what type of movement is best for you and to what extent you can exert yourself.

## **Body weight**

With a balanced diet and adequate exercise, you can reduce obesity in the long term. It is important not to eat more than your daily energy requirement. You can achieve this with a low-fat mixed diet rich in fibre and in appropriate portions.

## **Quit smoking**

Start a new smoke-free life. Your doctor will be happy to advise and support you in quitting smoking.

## **Regular medicine intake**

If you take medication to reduce blood sugar, ensure that intake is regular.

## **Diabetes education**

As part of a group diabetes discussion, you can find out everything worth knowing about diabetes, so that you can take action autonomously under your own responsibility.

# THIS IS HOW YOUR EYES ARE EXAMINED

## Visual acuity examination

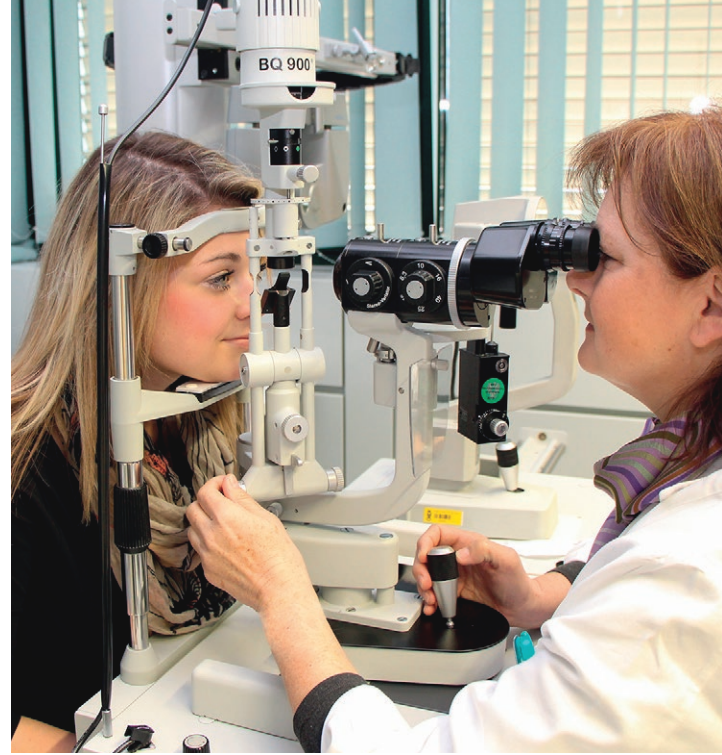This test is carried out with a visual acuity card. You are positioned 5–6 m from the card. Your eyesight is determined first without and then with the best possible diopetre correction. The examination takes place separately for each eye – for distance and close up.

## Examination of the front part of the eye

The eyelid, sclera, cornea, iris and lens are examined with the slit lamp, whereby an intense light source is focused as a slit. This examination also serves to measure eye pressure with a special attachment. The slit lamp looks like a microscope with two oculars.

## Examination of the eyeground (fundoscopy)

The examination is carried out with a dilated pupil (mydriasis) to be able to assess the external retinal areas.



The vitreous humour, optic nerve, macula, vessels and retina are examined – either through a suitable magnifier or by means of a contact lens examination.

## Examination of the eyeground with OCT (Optical Coherence Tomography)

A precise layered examination of the eyeground (especially the macula region, for the early identification or differentiation of moist-dry macula change, as well as the vessels) and of the vitreous humour.

# THE EYE

The eye allows us to perceive the world, to see dangers quickly and to move through our surroundings safely. Light reflected in the outside world is sent through the cornea, anterior eye chamber, pupil, lens and vitreous humour to the retina. From there, the gathered light signals are transmitted further through the optic nerve and the visual pathway to the brain and processed into an image.

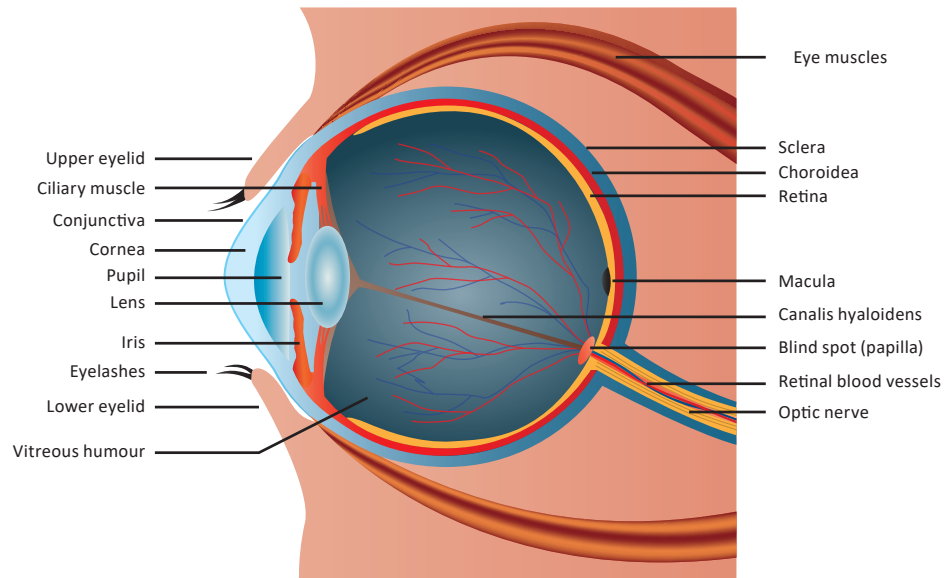


Abbildung: © bilderzweg/Fotolia.com

The tiny blood vessels of the retina can be damaged by elevated blood sugar levels. This endangers the eyesight. The diabetic can be unaware of these threatening changes for a long time. In order to identify them as soon as possible, in the Active Therapy programme special importance is attached to regular ophthalmological examinations.

## FURTHER DAMAGING FACTORS ARE:

- ... Consistently high blood pressure
- ... Long-lasting diabetes
- ... Hormonal changes (puberty, pregnancy)
- ... Smoking
- ... Strong blood sugar fluctuations
- ... Elevated blood fats



As part of Active Therapy, an annual visit to the ophthalmologist is recommended.

# HOW DO I HANDLE IT CORRECTLY?

- ... Have your eyes examined **once a year**. If complications have already occurred, your ophthalmologist in charge will call you in more often.
- ... In case of any **change to your eyesight**, contact your Active Therapy doctor immediately. Avoid **smoking**. Ensure a **good metabolism** as well as **good blood sugar and blood pressure levels**.
- ... Be physically active – **exercise** promotes good blood sugar levels. **Note:** in case of an existing retinopathy, you should avoid heavy physical exertion. Discuss the type of sport, duration and intensity with your Active Therapy doctor in charge.
- ... Take your **medication regularly**.
- ... A lasting **poor blood sugar balance** often leads to fluctuations in visual acuity. Especially during the adjustment phase with insulin, these can be very pronounced.
- ... For this reason, you should only carry out eye tests for **new glasses** with a stable blood sugar level.
- ... In case of significant diabetically induced fluctuations of visual acuity, avoid **driving a car**.





# WHAT CAN HAPPEN?

## Diabetic retinopathy

**Diabetic retinopathy is among the most frequent causes of blindness in adults. It can occur in both type 1 and type 2 diabetes. There are various types of diabetic retinopathy:**

### Non-proliferative retinopathy

The retina initially receives a poorer circulation. It leads to the formation of vessel bulges (microaneurysms) that can burst and bleed into the retina. As a consequence, fluid, fats and proteins also get into the retina. As long as these occurrences do not affect the macula (the central part of the retina), they do not usually cause complaints.

### Proliferative retinopathy

If the disease progresses, new vessels grow (proliferations) in an attempt to compensate for the poor blood flow. However, these are not stable and burst easily. They can either grow into the retina, bleed or lose fluid, or penetrate into the vitreous body and bleed into it. The scarring of the bleeding residue can lead to a detached retina. If the iris is affected, glaucoma can develop. Proliferative retinopathy usually leads to a lasting restriction of the eyesight, even to the extent of a loss of vision.



Initial stage  
of diabetic retinopathy



Advanced stage  
of diabetic retinopathy



Late stage  
of diabetic retinopathy

## SYMPTOMS

In the beginning the disease is mostly unnoticed. It is only in the advanced stage that complaints become evident.

- ... Those affected often have blurred vision
- ... If there is bleeding into the vitreous humour, it causes black spots that are also described as eye floaters.
- ... The loss of vision usually develops slowly, but in case of major bleeding or a detached retina it can also occur very suddenly.



## Treatment:

- ... Good blood sugar levels
- ... Treatment of further risk factors such as high blood pressure, diabetic renal disease, elevated blood fats
- ... Quitting smoking
- ... **Laser treatment:**  
Under local anaesthetic, altered areas on the retina are lasered and corrected. The progression of the diabetic retinopathy can

thus be slowed down. However, as a side effect of treatment, a restricted field of vision and visual disturbances in the dark and dusk can occur.

- ... **Operation:**

In case of a detached retina or bleeding in the vitreous humours, specific operations are needed.



As strong blood sugar fluctuations can affect eyesight, you should only have your new glasses adjusted when your blood sugar level is balanced.

## Macular oedema

The macula is the central area of the retina, where most of the sensory cells of the eye are located. It is responsible for seeing colour and for “sharp” vision, e.g. when reading or recognising faces. If the macula is affected by the described changes, fluid gathers there. It swells and loses its function, leading to a significant impairment of vision.

### SYMPTOMS

- ... The affected person normally notices a worsening of their eyesight.
- ... Central vision is impaired.
- ... Blurred and distorted vision, difficulty reading and a dark spot in the middle of the field of vision.

### Treatment

- ... Good blood sugar balance
- ... Treatment of further risk factors such as high blood pressure, diabetic kidney disease, elevated blood fats
- ... Quitting smoking
- ... **IVOM** (intravitreal operative medicine application with antiangiogenetic substances), counteracting the new development of harmful blood vessels, injected directly into the eye. Only if a significant loss of vision is identified during the monthly follow-up check is the injection repeated.
- ... **Laser treatment:**  
The aim of the laser treatment is the activation of the retinal base and of the immune system, to reduce the swelling, as well as to suppress retinal areas with poor circulation in order to reduce the oxygen requirement.
- ... **Corticosteroids:**  
The injection of these substances can lead to an eyesight improvement for some patients. However, this treatment is associated with a greater risk of glaucoma and cataracts.
- ... **Operation:**  
It can happen that the vitreous humour pulls on the middle of the retina and causes swelling. In such cases, the operative removal of the vitreous humour (vitrectomy) is the treatment of choice.





Normal vision



Vision with macular oedema

Foto: © GordonGrand/Fotolia.com

## Ischaemic maculopathy

A predominant obstruction of the blood vessels leads to a significant lack of oxygen and therefore to the death of the visual cells in the macula.

Contrary to macula oedema, the resulting loss of vision can no longer be treated.



Foto: © Monkey Business/Fotolia.com



**A good blood sugar balance is the basis for preventing eye diseases.**

## Clouding of the lens (cataracts)

Diabetes is also a risk factor for cataracts. These occur more frequently and earlier among diabetics and develop quicker. Cataracts are a clouding of the lens. It consists mainly of water and protein. If it clumps, it forms grey-white deposits in the lens. Those affected see their surroundings as if through a fog.

### SYMPTOMS

- ... Blotchy or dull vision
- ... Poor night vision
- ... Halos around bright light sources
- ... Sensitivity to light and dazzling

Cataracts usually develop slowly. The associated gradual loss of vision is often not even noticed. From the age of 65, a certain degree of lens clouding is natural. However, age alone does not explain the development of cataracts, because some people already have a cataract at birth.

### Treatment

Surgery is used for treatment. The clouded lens is removed and replaced by a precisely made artificial lens. Cataract surgery is very successful today for restoring eyesight.



Normal vision



Vision with cataracts

# THE AMSLER GRID TEST

Distorted and blurred vision can be verified by looking at the “Amsler grid” (self-test).


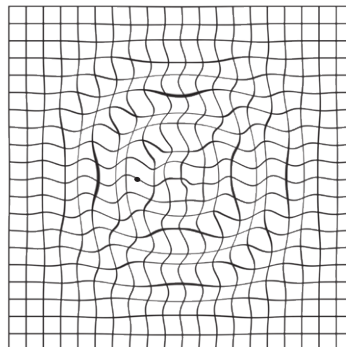

## This is how the test works:

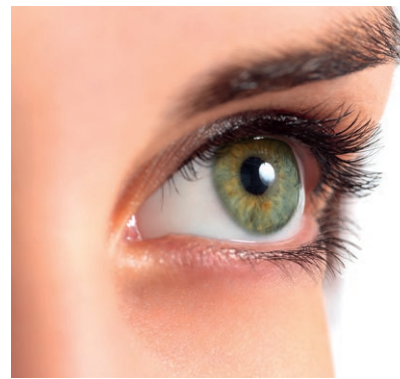Look at the grid in daylight from a distance of around 30–40 cm. If you normally wear glasses or contact lenses to read, then please also use these for the test. The test is carried out separately for each eye.

- ... First cover one eye with your hand, without squinting the eye shut.
- ... With the open eye, look at the black dot at the centre of the grid. What do you see?
- ... Repeat the test with the other eye.

## If you notice any of the following changes, you should consult your ophthalmologist:

- ... Do some squares of the grid appear bigger or smaller than the others?
- ... Is a corner missing from the grid?
- ... Can you see empty spaces?
- ... Are lines distorted or curved?
- ... Are certain areas of the grid blurred?
- ... Can you see a grey shadow?





“Active Therapy – Diabetes under control” is a treatment programme for patients with type diabetes mellitus. Ask your doctor about it!

**Contact:**

[office@therapie-aktiv.at](mailto:office@therapie-aktiv.at)

[www.therapie-aktiv.at](http://www.therapie-aktiv.at)



**IMPRINT NOTICE:**

Media owner and publisher: Österreichische Gesundheitskasse, Haidingergasse 1, 1030 Vienna

[www.gesundheitskasse.at/impressum](http://www.gesundheitskasse.at/impressum)

Editorial: ÖGK Landesstelle Steiermark (Styrian Regional Branch), Josef-Pongratz-Platz 1, 8010 Graz

Title photos/images: © Croce & Wir; Antonioguilllem, Viacheslav Anyakin, snyfer/Fotolia.com

Producer: VENDO Kommunikation + Druck GmbH | [vendo.at](http://vendo.at)

Printed 2025

